SCIENTIFIC ARTICLE

Preoperative Donor Nerve Electromyography as a Predictor of Nerve Transfer Outcomes

Joseph J. Schreiber, MD, Joseph H. Feinberg, MD, David J. Byun, BS, Steve K. Lee, MD, Scott W. Wolfe, MD

Purpose We hypothesized that health of the donor nerve and corresponding muscle, as assessed by electromyography (EMG), could predict the outcome of nerve transfer surgery.

Methods A retrospective review was performed to investigate outcomes of nerve transfers for elbow flexion and shoulder abduction. Motor strength was graded preoperatively and after a minimum 1-year follow-up. Preoperative EMG results were classified as functionally *normal* or *affected* based on motor unit recruitment pattern and correlated with follow-up motor strength and range of motion.

Results Forty nerve transfers were identified: 27 were performed for elbow flexion and 13 for shoulder abduction. Overall, the 29 transfers in the *normal* EMG cohort showed significantly greater postoperative improvement in motor strength (Medical Research Council grade 0.2−4.1) than the 11 transfers in the *affected* EMG cohort (grade 0.0−3.0). In the shoulder cohort, normal donor nerves resulted in greater strength (grade 4.0 vs. 2.4) and active motion (83° vs. 25°) compared with affected donor nerves. Double fascicular transfers with 2 normal donor nerves demonstrated improved strength compared with double nerve transfers when 1 donor nerve was affected (grade 4.5 vs. 3.2).

Conclusions Our findings demonstrate that a simple EMG classification that describes the quality of donor nerves can predict outcome as measured by postoperative motor strength and range of motion. Preoperative EMG evaluation should be considered a valuable supplementary component of the donor nerve selection process when planning brachial plexus reconstruction. *(J Hand Surg Am. 2014;39(1):42−49. Copyright © 2014 by the American Society for Surgery of the Hand. All rights reserved.)*

Type of study/level of evidence Prognostic II.

Key words Nerve transfer, brachial plexus, electromyography.

Brachial plexus injuries are catastrophic events that can produce debilitating limitations of shoulder, elbow, and hand function.[1,2] In C5−6, or upper trunk injuries, restoration of elbow flexion is of primary importance, followed by the need for shoulder stability, external rotation, and abduction.[1,3−5] Whereas various interventions including nerve repair or nerve grafting have traditionally played a central role in plexus reconstruction, nerve transfer has assumed increasing importance because of the relative short reinnervation distances, reliable and robust axon sources, and the steadily expanding variety of nerve transfer options available for these complex injuries.[6−9]

In 1994, Oberlin et al[3] described a transfer using fascicles of the ulnar nerve to the biceps motor branch to restore elbow flexion. This was followed by several reports documenting restoration of biceps function with minimal ulnar nerve donor site morbidity.[1,5,10−16]

From the Center for Brachial Plexus and Traumatic Nerve Injury, Hospital for Special Surgery, New York, New York.

Received for publication July 28, 2013; accepted in revised form September 26, 2013.

No benefits in any form have been received or will be received related directly or indirectly to the subject of this article.

Corresponding author: Scott W. Wolfe, MD, Center for Brachial Plexus and Traumatic Nerve Injury, Hospital for Special Surgery, 535 East 70th St., New York, NY 10021; e-mail: wolfes@hss.edu.

0363-5023/14/3901-0008$36.00/0
http://dx.doi.org/10.1016/j.jhsa.2013.09.042

Besides addressing elbow flexion, restoring shoulder abduction and external rotation is critical to increase the total functional sphere of the upper extremity.[4] At a minimum, a stable glenohumeral joint is essential to prevent dissipation of elbow flexion force into proximal humeral migration. A technique involving transfer of the long head triceps branch to the deltoid branches of the axillary nerve gained popularity following early outstanding results.[4] When performed together, Oberlin and triceps-to-axillary nerve transfers are a reliable and effective technique for functional recovery of elbow flexion as well as shoulder abduction in C5−6 and upper trunk brachial plexus injuries.[1,5,15,17]

Several factors have been identified that may predict success of nerve transfers including patient age,[18−21] time from injury to surgery,[14,18,21−23] body mass index,[18] and the number of active motor neurons in the donor fascicle.[24,25]

Electromyography (EMG) is often used before surgery to assess electrical conduction, muscle denervation, and the presence of functional motor units in patients with brachial plexus injuries.[26] The use of EMG during surgery has been explored to choose the optimal donor fascicles, and motor outcomes have been correlated with evoked potential patterns.[27]

Preoperative EMG of potential donor nerves may show abnormalities in muscles that appear normal clinically. This presents a dilemma to the surgeon in determining whether fascicles of the donor nerve could be transferred with expectation of success. Most authors recommend choosing donor nerves from muscles with clinically normal (British Medical Research Council [MRC] grade 5) or minimally affected (MRC grade 4 or 4+). We hypothesized that health of the donor nerve and its corresponding muscle, as assessed by EMG, could help predict the outcome of nerve transfer surgery.

MATERIALS AND METHODS

An institutional review board−approved retrospective review of our prospective Health Insurance Portability and Accountability Act−compliant traumatic nerve injury registry was performed to investigate the outcomes of 2 common nerve transfers performed over the past decade: (1) ulnar or median nerve fascicular branch transfer to the biceps or brachialis motor branches and (2) long or medial head triceps branch transfer to motor branches of the axillary nerve. A minimum of 1-year clinical follow-up after nerve transfer was required for inclusion in the study. Exclusion criteria included abnormal clinical strength in the donor nerve distribution (<M4), incomplete preoperative EMG evaluation of both the donor and the recipient nerves, or lack of 1-year follow-up. Forty such transfers were identified, with 16 transfers to the biceps, 11 transfers to the brachialis, and 13 transfers to the deltoid.

All patients underwent detailed preoperative clinical examination including motor strength evaluation according to the modified MRC grading system, range of motion measurements, and sensory examination. Throughout the study, MRC grading of muscles in the donor nerve distributions included triceps strength for radial nerve evaluation; flexor carpi ulnaris muscle, ulnar portion of the flexor digitorum profundus, and first dorsal interosseous muscle for ulnar nerve evaluation; and flexor carpi radialis, pronator, flexor pollicis longus, and abductor pollicis brevis for median nerve evaluation. Preoperative motor strength in the innervated muscles of the donor nerve distribution was required to be M4 or M5 for consideration of nerve transfer.

All donor nerves (ulnar, median, radial) were evaluated before surgery by EMG. All EMG evaluations were performed and interpreted by a single electrodiagnostic expert. The donor nerve distribution EMG results were retrospectively classified as functionally normal or affected based on the recorded motor unit recruitment patterns. Recruitment is an evaluation of functional motor units and is graded on a 4-category scale: full, decreased, discrete, or none (Fig. 1). Full motor recruitment occurs when there is complete motor unit activation and the EMG screen is entirely filled. Decreased recruitment occurs when there is a large quantity of motor units firing, the entire EMG screen is not filled, but individual motor units cannot be identified. Discrete recruitment pattern shows a smaller quantity of motor units firing, resulting in individual motor units being identifiable during maximum effort. We defined functionally normal donor nerves as those that displayed either full or decreased recruitment patterns in all of the muscles within the nerve's innervation territory. Functionally affected donor nerves displayed a discrete pattern or complete lack of motor recruitment in some or all of the muscles within the nerve's innervation territory.

The presence of abnormal spontaneous activity in the form of positive sharp waves and fibrillations was also recorded on a scale of 0 to 4+. Zero is the absence of fibrillations or positive sharp waves, 1+ is persistent/unsustained single trains in at least 2 muscle regions, 2+ is moderate numbers in 3 or more muscle areas, 3+ is many in all muscle regions, 4+ is an

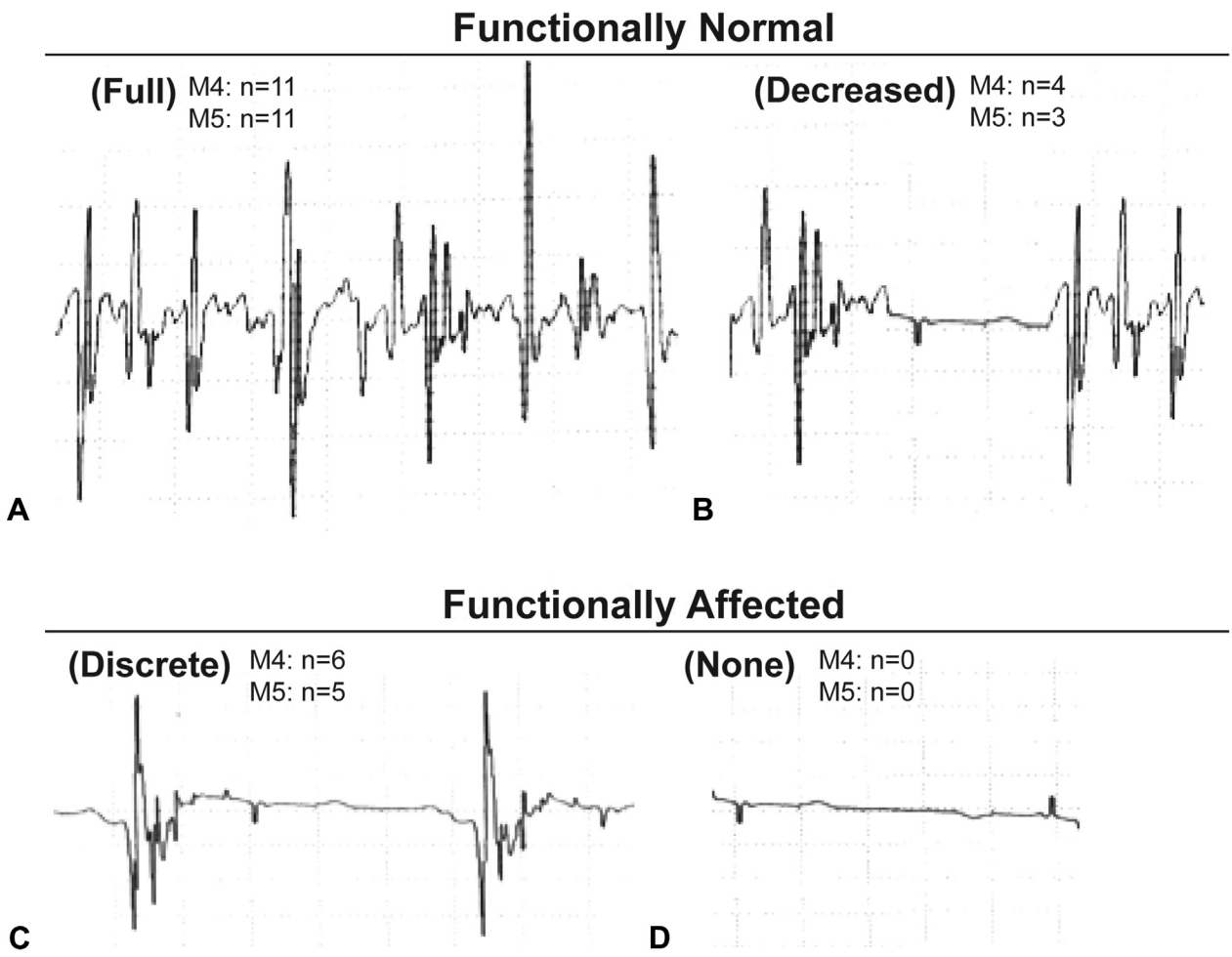

FIGURE 1: EMG classification system. Functionally normal donor nerves displayed full **A** or decreased **B** motor unit recruitment patterns. Functionally affected donor nerves displayed either discrete **C** or a recruitment pattern of none **D**. The corresponding donor nerve distribution motor strength grades and frequency are also displayed.

obliteration of the baseline with fibrillation potentials in all areas of muscle examined.[28] A score of 0 to 2 was considered low-grade abnormal spontaneous activity, whereas a grade of 3 to 4 was considered high grade.

Follow-up was performed at a minimum of 1 year, and the examiner was blinded as to the EMG findings and surgical technique used. Motor strength in the recipient muscle distribution was evaluated using the modified MRC grading scheme. The range of shoulder abduction and the arc of elbow flexion-extension was measured by a hand-held goniometer. Donor site morbidity was assessed with appropriate sensibility evaluation and MRC grading of distally innervated muscles of the donor nerve.

Statistical analysis

Data on motor strength were examined for normality; and given the small sample size, nonparametric tests were used for data analysis. A 2-tailed Mann-Whitney U test was used to compare differences in improvement in motor strength between the cohorts with functionally normal and affected preoperative donor nerve EMG results. A post hoc power analysis was then completed to ensure adequate power using the differences in MRC graded muscle strength as the primary outcome and a clinically significant difference of 1.0 unit. Descriptive statistics were calculated for demographic variables, range of motion improvements, and frequency of abnormal spontaneous activity findings. A 2-tailed Student *t*-test was used to compare means of continuous variables with an alpha value of $P = 0.05$, and a chi-square test was used for categorical variables.

RESULTS

A total of 40 nerve transfers were identified that had met all inclusion and exclusion criteria (Table 1).

TABLE 1. Patient Characteristics

	Functionally Normal Preoperative EMG	Affected Preoperative EMG	*P* Value
N (total)	29	11	
N (elbow flexion)	21	6	
N (shoulder abduction)	8	5	
Mean age (y)	38	36	.71
Elbow cohort	37	29	.19
Shoulder cohort	39	44	.59
Sex (M:F)	28:1	10:1	.46
Preoperative donor nerve distribution strength			
M4 (%)	52	55	.87
M5 (%)	48	45	
Mean follow-up (wk)	92	93	.96
Elbow cohort	93	111	.44
Shoulder cohort	89	71	.49
Time from injury to surgery (d)	158	177	.56
Elbow cohort	160	174	.74
Shoulder cohort	154	181	.66
Time from EMG to surgery (d)	32	24	.33

There were no descriptive or demographic differences identified between the functionally normal and the affected EMG cohorts, either in aggregate or when subdivided by type of transfer. In addition, there were no differences in the preoperative muscle strength in the territory of the donor nerves used (Fig. 1).

Those patients with functionally normal donor nerve EMG evaluations showed significantly greater improvements in postoperative motor strength ($P < .01$) when compared with those performed with affected motor nerves (Fig. 2). Within the normal EMG cohort, there were no differences in improvements ($P = .44$) between those patients with full motor unit recruitment and those with decreased recruitment patterns. All patients in the affected EMG cohort had discrete recruitment patterns because no nerves with a recruitment pattern graded as none were used as donors.

Data were also subanalyzed by type of transfer. In the patients with transfers for elbow flexion, MRC grade was not significantly different between normal and affected donor nerves (Fig. 3). Mean active elbow motion increased from 2° to 126° in the normal EMG cohort compared with an increase from 0° to 109° in the affected cohort ($P = .42$). We observed a trend toward an increased proportion (18 of 21; 86%) of patients in the functionally normal EMG cohort gaining M4 elbow flexion strength compared with 3 of 6 (50%) patients in the affected cohort ($P = 0.06$). In the 9 patients with double nerve transfers for elbow flexion, those individuals with 2 normal donor nerves had greater improvements in strength (n = 4; increased from 0.0 to 4.5) compared with those individuals with 1 normal and 1 affected donor nerve (n = 5; increased from 0.0 to 3.2), ($P < .01$).

In the triceps-to-axillary transfer cohort, the functionally normal EMG patients showed significantly greater improvements in both motor strength and active shoulder abduction motion. Mean deltoid MRC grade increased significantly more in the functionally normal EMG cohort compared with the affected EMG cohort (Fig. 4). Active shoulder abduction improved from 10° to 83° in the functionally normal EMG cohort compared with 0° to 25° in the affected cohort ($P < .01$). All 8 patients (100%) with a functionally normal donor nerve EMG results gained M4 deltoid strength compared with 0 of 5 (0%) in the affected cohort ($P < .001$).

Muscle strength of M4 versus M5 in the donor nerve distribution was independently assessed as a predictor for postoperative strength outcomes. There were no differences in the total cohort ($P = .35$), the elbow cohort ($P = .18$), or the shoulder cohort ($P = .94$).

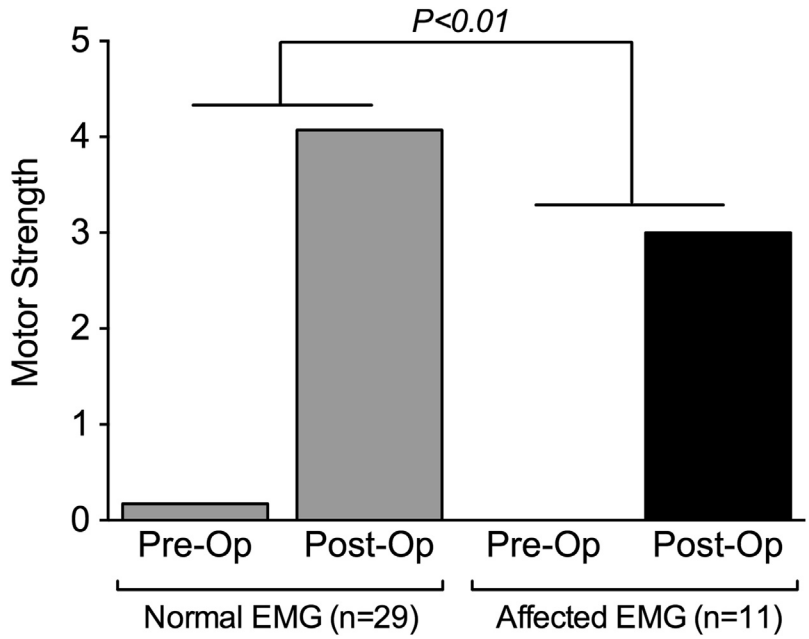

FIGURE 2: Aggregate data. Combined data of pre- and postoperative motor function following nerve transfer. The patients with functionally normal EMG findings had significantly greater improvements in postoperative motor strength ($P < .01$).

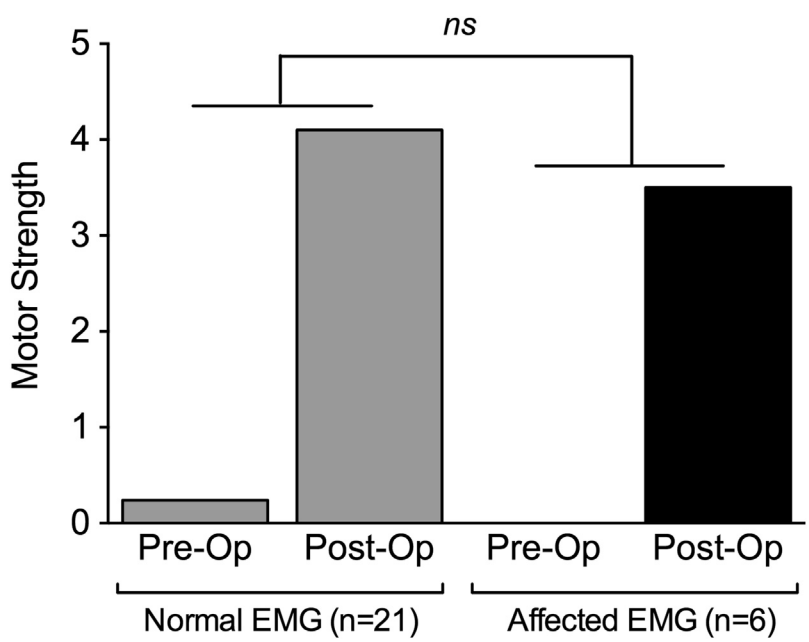

FIGURE 3: Elbow flexion cohort. Pre- and postoperative elbow flexion strength in patients who underwent transfer of ulnar or median nerve fascicles to musculocutaneous branches to the biceps or brachialis muscles. The greater improvements in the functionally normal EMG cohort did not reach statistical significance ($P = .41$).

The functionally affected EMG cohort showed increased prevalence of high-grade abnormal spontaneous muscle activity (Fig. 5) in the form of both fibrillations ($P < .001$) and positive sharp waves ($P < .001$).

Postoperative clinical examination demonstrated no evidence of sensory or motor donor nerve morbidity in any patient.

DISCUSSION

Our findings demonstrate that donor nerves with functionally normal or near-normal preoperative EMG have improved postoperative motor strength outcomes compared with affected nerves. All muscles within our donor nerve territories were clinically strong (M4 or M5), and post hoc statistical analysis

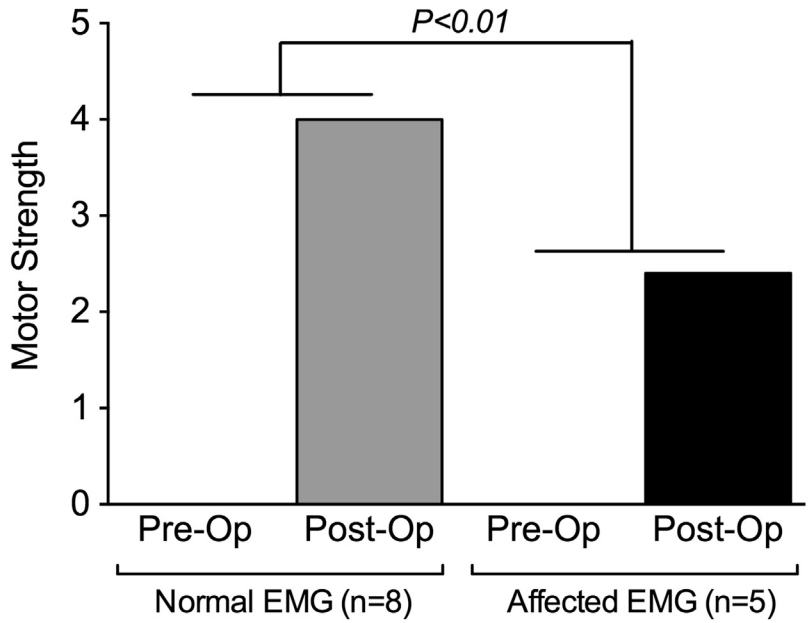

FIGURE 4: Shoulder abduction cohort. Pre- and postoperative shoulder abduction strength in patients who underwent long or medial head triceps branch transfer to the axillary nerve. The patients with functionally normal EMG findings had significantly greater improvements in postoperative motor strength ($P < .01$).

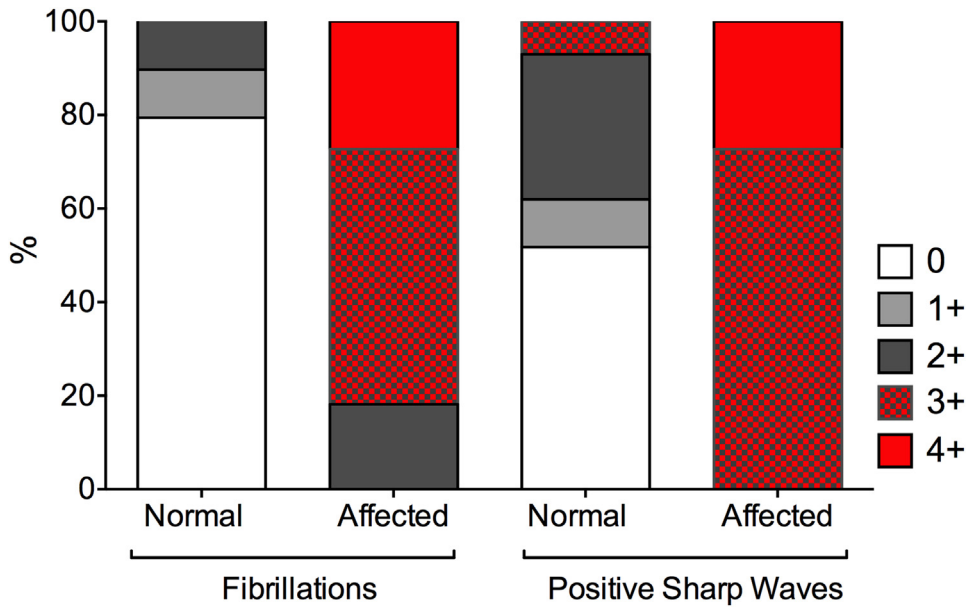

FIGURE 5: Additional EMG findings. Presence of fibrillations and positive sharp waves (graded 0−4+) seen in the functionally normal and affected EMG cohorts. High-grade abnormal spontaneous muscle activity (grade 3−4+ fibrillations and positive sharp waves) were significantly more common in the affected EMG cohort ($P < .001$).

demonstrated no differences in functional outcome based on preoperative MRC grading, suggesting that preoperative clinical assessment of motor strength is inadequate to assess the utility of a potential donor nerve. Our results demonstrate that preoperative EMG findings of motor recruitment pattern appear to provide a more discernible evaluation of the donor nerve's overall health than clinical examination alone.

Suzuki et al[27] used intraoperative electrodiagnostic testing during ulnar nerve to biceps transfer. The fascicle producing the highest amplitude in the flexor carpi ulnaris was chosen for transfer in 6 patients and resulted in M4 outcomes in all. The 2 control patients

who did not have intraoperative EMG performed did not achieve clinically useful biceps strength. Although useful, the technique is qualitative and does not permit preoperative selection of potential donor fascicles or selection of a particular donor nerve based on specific EMG parameters.

We recommend donor nerve EMG status as a useful parameter to improve the likelihood of success following nerve transfer surgery. Motor unit recruitment pattern appears most indicative of donor nerve health and function; however, frequency of high-grade abnormal spontaneous activity in the form of fibrillations and positive sharp waves also differed between cohorts (Fig. 5).

Previously identified factors that correlate with functional outcomes include age,[18–21] delay between injury and nerve transfer,[14,18,21–23] body mass index,[18] and the number of functional motor neurons in the donor fascicle.[24,25] We controlled for these factors in our analysis and found no significant differences between the normal and the affected EMG cohorts in this regard (Table 1).

Our data on postoperative motor strength results are comparable with historical data on similar transfers.[1,3,5,10–16] In our series, 22 of 27 patients (81%) gained biceps flexion strength of MRC grading M4 or higher. However, if only those transfers that used a normal donor nerve are analyzed, 18 of 21 patients (86%) gained biceps flexion strength of M4 or higher compared with 3 of 6 (50%) in the affected cohort.

In this study, no differences in elbow flexion outcomes were observed between the normal and the affected cohorts. We believe that the routine use of double nerve transfers for elbow flexion likely obscured the potential denervation effect because normal donor innervation of one transfer seemed to compensate for the affected donor nerve innervation of another. When we subdivided the elbow transfer group into double normal, single affected, and double affected, we found significantly greater improvements in strength when 2 healthy donor nerves were used compared with 1 normal and 1 affected. We did not perform transfers with 2 affected nerve fascicles. When 2 normal fascicles were used for a double nerve transfer, all patients had M4 or greater functional outcome. This is important, considering the finite failure rate of nerve transfer surgery for elbow flexion,[1,3,5,10–16] and suggests that EMG assessment of potential donor nerves should be a routine part of the preoperative evaluation.

In our triceps-to-axillary nerve transfer cohort, M3 or greater power in the deltoid was achieved in 11 of 13 patients (85%) and M4 strength in 8 of 13 patients (62%). Outcomes were superior in the functionally normal donor nerve EMG cohort because all 8 patients (100%) gained M4 deltoid strength compared with 0 of 5 (0%) in the affected cohort. The functionally normal EMG cohort also had significantly greater improvements in active shoulder abduction motion. In the report by Leechavengvongs et al,[4] all 7 patients obtained M4 power, and in their subsequent series,[5] 13 of 15 achieved M4 power whereas the remaining 2 were graded as M3. Estrella[15] reported M3 or greater deltoid power in 8 of 9 patients (89%), and Bertelli et al[1] showed 7 of 10 patients regained M3 strength and 3 gained M4 strength. In a study by Lee et al,[18] 16 of 21 patients (76%) with isolated axillary nerve palsies gained M3 or better strength following triceps to deltoid transfer. Preoperative electrodiagnostic evaluations were not reported in this or the previously cited studies.

Considering the secondary outcome, no changes in donor nerve distribution motor strength or sensibility were identified after surgery in any patient. Therefore, although functionally affected preoperative EMG results may predict less reliable motor strength improvements, it does not appear that these EMG findings increase the likelihood of donor site morbidity. Lack of donor site morbidity has been documented in previous studies. Following Oberlin transfers, examinations of distally innervated ulnar nerve motor groups have shown no decline in strength.[11,12] Paradoxically, some studies have found significant improvement in grip strengths measured after surgery, perhaps due to synergistic effects from recovery of elbow flexion strength or alternatively due to further spontaneous recovery occurring during the follow-up period.[2,11] When complications in sensory and motor function of the donor nerve were observed after surgery, these morbidities appear to be transient in nature.[3,12,15] Similar to observations seen following Oberlin transfers, triceps-to-axillary transfers have not shown donor site morbidity or loss of strength.[4,5]

Based on the results of this study, when planning nerve surgery for restoration of elbow flexion, we advocate performing a double fascicular transfer with at least 1 healthy nerve donor if either the ulnar or the median nerve displayed a discrete recruitment pattern downstream. If both ulnar- and median-innervated muscles are compromised, we would consider medial pectoral, thoracodorsal, or intercostal nerves as potential donors. For deltoid reinnervation, if all 3 triceps branches of the radial nerve were electromyographically compromised, we would select a healthy thoracodorsal or medial pectoral nerve.

Alternatively, if the C5 or C6 nerve roots were available, a long graft to the axillary nerve is another excellent option.

REFERENCES

1. Bertelli JA, Ghizoni MF. Reconstruction of C5 and C6 brachial plexus avulsion injury by multiple nerve transfers: spinal accessory to suprascapular, ulnar fascicles to biceps branch, and triceps long or lateral head branch to axillary nerve. *J Hand Surg Am*. 2004;29(1):131−139.
2. Ray WZ, Pet MA, Yee A, Mackinnon SE. Double fascicular nerve transfer to the biceps and brachialis muscles after brachial plexus injury: clinical outcomes in a series of 29 cases. *J Neurosurg*. 2011;114(6):1520−1528.
3. Oberlin C, Beal D, Leechavengvongs S, Salon A, Dauge MC, Sarcy JJ. Nerve transfer to biceps muscle using a part of ulnar nerve for C5-C6 avulsion of the brachial plexus: anatomical study and report of four cases. *J Hand Surg Am*. 1994;19(2):232−237.
4. Leechavengvongs S, Witoonchart K, Uerpairojkit C, Thuvasethakul P. Nerve transfer to deltoid muscle using the nerve to the long head of the triceps, part II: a report of 7 cases. *J Hand Surg Am*. 2003;28(4):633−638.
5. Leechavengvongs S, Witoonchart K, Uerpairojkit C, Thuvasethakul P, Malungpaishrope K. Combined nerve transfers for C5 and C6 brachial plexus avulsion injury. *J Hand Surg Am*. 2006;31(2):183−189.
6. Narakas AO, Hentz VR. Neurotization in brachial plexus injuries. Indication and results. *Clin Orthop Relat Res*. 1988;237:43−56.
7. Guelinckx PJ, Carlson BM, Faulkner JA. Morphologic characteristics of muscles grafted in rabbits with neurovascular repair. *J Reconstr Microsurg*. 1992;8(6):481−489.
8. Brandt KE, Mackinnon SE. A technique for maximizing biceps recovery in brachial plexus reconstruction. *J Hand Surg Am*. 1993;18(4):726−733.
9. Tung TH, Mackinnon SE. Nerve transfers: indications, techniques, and outcomes. *J Hand Surg Am*. 2010;35(2):332−341.
10. Loy S, Bhatia A, Asfazadourian H, Oberlin C. Ulnar nerve fascicle transfer onto to the biceps muscle nerve in C5-C6 or C5-C6-C7 avulsions of the brachial plexus. Eighteen cases [in French]. *Ann Chir Main Memb Super*. 1997;16(4):275−284.
11. Leechavengvongs S, Witoonchart K, Uerpairojkit C, Thuvasethakul P, Ketmalasiri W. Nerve transfer to biceps muscle using a part of the ulnar nerve in brachial plexus injury (upper arm type): a report of 32 cases. *J Hand Surg Am*. 1998;23(4):711−716.
12. Sungpet A, Suphachatwong C, Kawinwonggowit V, Patradul A. Transfer of a single fascicle from the ulnar nerve to the biceps muscle after avulsions of upper roots of the brachial plexus. *J Hand Surg Br*. 2000;25(4):325−328.
13. Teboul F, Kakkar R, Ameur N, Beaulieu JY, Oberlin C. Transfer of fascicles from the ulnar nerve to the nerve to the biceps in the treatment of upper brachial plexus palsy. *J Bone Joint Surg Am*. 2004;86(7):1485−1490.
14. Sedain G, Sharma MS, Sharma BS, Mahapatra AK. Outcome after delayed Oberlin transfer in brachial plexus injury. *Neurosurgery*. 2011;69(4):822−827; discussion 827−828.
15. Estrella EP. Functional outcome of nerve transfers for upper-type brachial plexus injuries. *J Plast Reconstr Aesthet Surg*. 2011;64(8):1007−1013.
16. Venkratramani H, Bhardwaj P, Faruquee SR, Sabapathy SR. Functional outcome of nerve transfer for restoration of shoulder and elbow function in upper brachial plexus injury. *J Brachial Plex Peripher Nerve Inj*. 2008;3:15.
17. Mackinnon SE, Novak CB, Myckatyn TM, Tung TH. Results of reinnervation of the biceps and brachialis muscles with a double fascicular transfer for elbow flexion. *J Hand Surg Am*. 2005;30(5):978−985.
18. Lee JY, Kircher MF, Spinner RJ, Bishop AT, Shin AY. Factors affecting outcome of triceps motor branch transfer for isolated axillary nerve injury. *J Hand Surg Am*. 2012;37(11):2350−2356.
19. Verdu E, Ceballos D, Vilches JJ, Navarro X. Influence of aging on peripheral nerve function and regeneration. *J Peripher Nerv Syst*. 2000;5(4):191−208.
20. El-Gammal TA, El-Sayed A, Kotb MM. Surgical treatment of brachial plexus traction injuries in children, excluding obstetric palsy. *Microsurgery*. 2003;23(1):14−17.
21. Liverneaux PA, Diaz LC, Beaulieu JY, Durand S, Oberlin C. Preliminary results of double nerve transfer to restore elbow flexion in upper type brachial plexus palsies. *Plast Reconstr Surg*. 2006;117(3):915−919.
22. Ricardo M. Surgical treatment of brachial plexus injuries in adults. *Int Orthop*. 2005;29(6):351−354.
23. Bentolila V, Nizard R, Bizot P, Sedel L. Complete traumatic brachial plexus palsy. Treatment and outcome after repair. *J Bone Joint Surg Am*. 1999;81(1):20−28.
24. Wood MB, Murray PM. Heterotopic nerve transfers: recent trends with expanding indication. *J Hand Surg Am*. 2007;32(3):397−408.
25. Kakinoki R, Ikeguchi R, Dunkan SF, et al. Comparison between partial ulnar and intercostal nerve transfers for reconstructing elbow flexion in patients with upper brachial plexus injuries. *J Brachial Plex Peripher Nerve Inj*. 2010;5(1):4.
26. O'Shea K, Feinberg JH, Wolfe SW. Imaging and electrodiagnostic work-up of acute adult brachial plexus injuries. *J Hand Surg Eur Vol*. 2011;36(9):747−759.
27. Suzuki O, Sunagawa T, Yokota K, et al. Use of quantitative intra-operative electrodiagnosis during partial ulnar nerve transfer to restore elbow flexion: the treatment of eight patients following a brachial plexus injury. *J Bone Joint Surg Br*. 2011;93(3):364−369.
28. Dumitru D. *Electrodiagnostic Medicine*. Philadelphia: Hanley & Belfus; 1994:231.